



**PATIENT**

Goliath Cassista

**PRESENTING CLINICAL SIGNS**

History: Recently had TPLO surgery; at time of surgery a new grade 2/6 heart murmur was heard. This murmur was not audible while under GA. Heart murmur has persisted; grade II PMI left side.

**SPECIES**

Canine

**ECHOCARDIOGRAM FINDINGS**

2D, m-mode, color flow and doppler imaging is available. Minimal diffuse thickening of mitral valve leaflets with no obvious prolapse into the left atrial lumen. No mitral regurgitation is identified. Normal left atrial dimension. Normal LV diameter with adequate myocardial function. The tricuspid valve appears subjectively normal, with no tricuspid regurgitation. The right heart is normal (subjective). No overt evidence of pulmonary arterial hypertension. The pulmonic and aortic valves are normal in morphology and mobility. No aortic abnormalities identified, however the LVOT velocity is mildly elevated. Normal pulmonic outflow velocities. No aortic or pulmonic insufficiency. No pericardial or pleural effusion noted. No cardiac tumors observed.

**BREED**

English Bulldog

**SEX**

Male

**CARDIAC CHART**

**AGE**

22 months

**WEIGHT**

73.9lbs

**INTERPRETED BY**

Maggie Machen Lamy,  
DVM, DACVIM  
(Cardiology)

**IMAGING PERFORMED BY**

Mark van Campen,  
DVM

**HOSPITAL NAME**

Mississippi Hills  
Animal Hospital

**REFERRING VET**

Dr. van Campen

**INVOICE**

30697

**DATE**

5/9/23

CANINE CARDIAC PARAMETERS	MR VMAX (m/s)	TR VMAX (m/s)	LA/AO (Boon method)	LA/AO (Heart Base; Swe)	FS (%)	EF (%)	EPSS (cm)
NORMAL PARAMETER	4.5-5.5	<2.7	1.3	<1.6	28-40	40-100	<0.6
PATIENT	NA	NA	NM	1.3	32	60	NM
CANINE CARDIAC PARAMETERS	HR (BPM)	AV VMAX (m/s)	PV MAX (m/s)	BODY WEIGHT (kg)	LA 2D short axis Base view (cm)	LVIDd Avg; 2D and m-mode short axis (cm)	LVIDs Avg; 2D and m-mode short axis (cm)
NORMAL PARAMETER	50-100	0.7-1.7	0.7-1.6	BELOW	BELOW	BELOW	BELOW
PATIENT	NM	2.2	1.4	33.5	2.1	3.7	2.5
*Normal chamber parameters expressed as a mean value (SD)				3	1.27 (5.3)	2.46 (2.46)	1.36 (5.5)
<b>BODY WEIGHT DEPENDENT PARAMETERS</b>				5	1.40 (4.5)	2.74 (5.2)	1.60 (4.7)
<i>*Note: All measurements based upon multi-modal images and methods. An average value is reported.</i>				10	1.50 (3.8)	3.27 (3.5)	2.06 (3.1)
				15	1.83 (2.0)	3.71 (2.4)	2.43 (2.1)
				20	2.02 (1.9)	4.14 (2.2)	2.80 (2.0)
				25	2.18 (2.4)	4.48 (2.9)	3.10 (2.5)
				30	2.33 (3.3)	4.83 (3.9)	3.39 (3.4)
				35	2.48 (4.3)	5.17 (5.0)	3.69 (4.5)
				40	2.62 (5.2)	5.48 (6.1)	3.96 (5.4)
				50	2.88 (7.1)	6.07 (8.3)	4.46 (7.4)

Adapted from June Boon, Veterinary Echocardiography, 1998  
Rishniw M and Hollis NE, J Vet Intern Med 2000; 14:429-435  
Hansson et al, Vet Rad and Ultrasound 2002  
Bonagura et al. Echocardiography: principles of interpretation, Vet Clin North Am 15:1177, 1995

**INTERPRETATION OF THE FINDINGS & FURTHER RECOMMENDATIONS**

The only cause of a murmur identified is increased flow velocity through the LVOT/aortic root. No obvious subaortic ridge or valvular abnormalities are visualized, and in the absence of structural abnormalities this is considered a benign flow murmur. If this is a new murmur, it is reasonable to monitor periodically via recheck echocardiography in the future. Additionally screening for fluid status abnormalities (dehydration, anemia, etc.) is recommended through routine lab work as these abnormalities would make this finding more prevalent. No significant valvular insufficiencies were noted, and no structural issues identified.

No cardiac medications are indicated. No cardiac contraindication for general anesthesia.



**PATIENT**

Goliath Cassista

Monitor for any development of cough, labored breathing or exercise intolerance.

**SPECIES**

Canine

Recommend recheck echocardiogram in 12-18 months to screen for progression or development of concurrent cardiac disease that the preexisting murmur may mask.

**IMAGES**

**BREED**

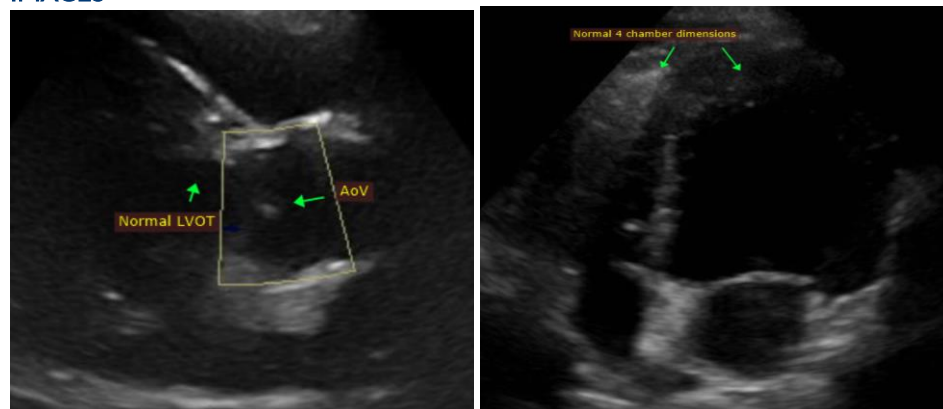
English Bulldog

**SEX**

Male

**AGE**

22 months



**WEIGHT**

73.9lbs

The information and recommendations provided are based on the images presented by the referring veterinarian. No evaluation can be communicated regarding pathology that was not visible in the image/video clips provided.

**INTERPRETED BY**

Maggie Machen Lamy,  
DVM, DACVIM  
(Cardiology)

Thank you for this referral. This report was generated using transcription software, and minor dictation errors may be present. If the clinical or image interpretation does not parallel your findings or if I can be of any further assistance, please contact me.

**Maggie Machen Lamy, DVM**  
Diplomate of the American College of Veterinary Internal Medicine (Cardiology)  
info@sonopath.com

**IMAGING PERFORMED BY**

Mark van Campen,  
DVM

**HOSPITAL NAME**

Mississippi Hills  
Animal Hospital

**REFERRING VET**

Dr. van Campen

**INVOICE**

30697

**DATE**

5/9/23